

Extralevatoire APR met reconstructietechnieken perineum

Prof. Dr. Hans de Wilt
Hoogleraar Chirurgische Oncologie
Radboudumc, Nijmegen

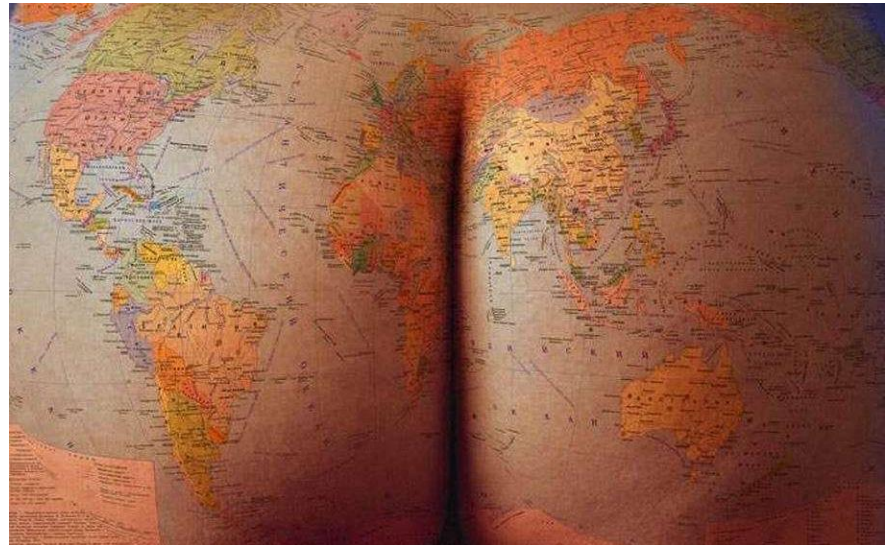
Radboudumc

Disclosure belangen spreker

(potentiële) Belangenverstremgeling	Geen
Voor bijeenkomst mogelijk relevante relaties met bedrijven	-
<ul style="list-style-type: none">• Sponsoring of onderzoeksgeld• Honorarium of ander (financiële) vergoeding• Aandeelhouder• Andere relaties, namelijk ...	<ul style="list-style-type: none">•• KWF, ZonMW, Bergh in het zadel, Metronic, Roche••

Perineale reconstructive na rectumchirurgie

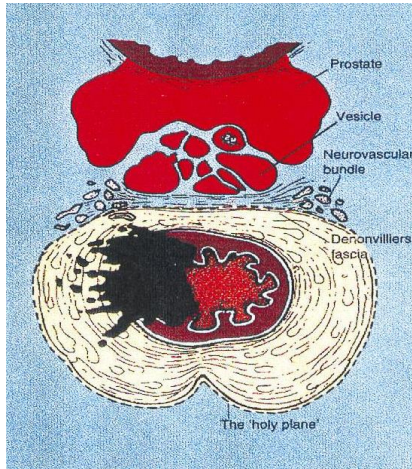
- Introductie rectumchirurgie
- Reconstructies
- Take Home Message



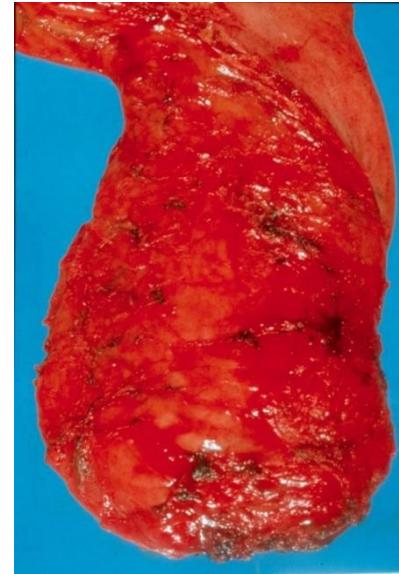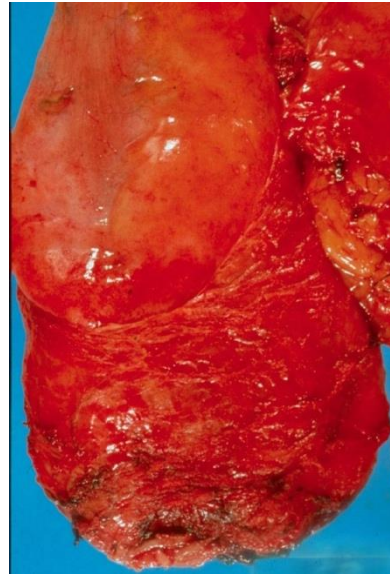
Rectumchirurgie

- Rectumcarcinoom
- Anuscarcinoom
- Sarcoom (GIST/Chordoom/SFT/...)
- IBD (Colitis Ulcerosa/Crohn)
- Trauma

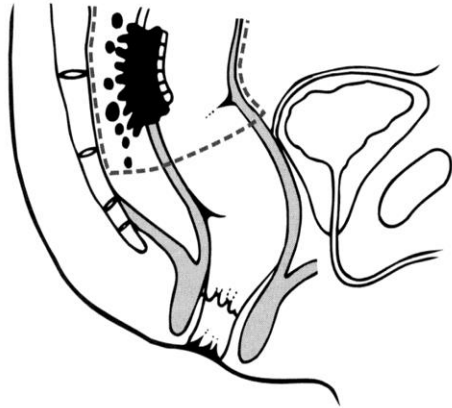
Totale mesorectale excisie



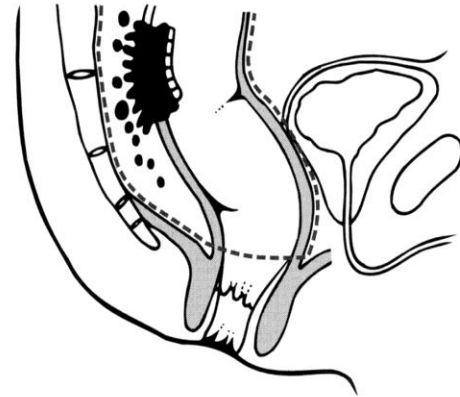
Standard therapie



Mesorectale Excisie

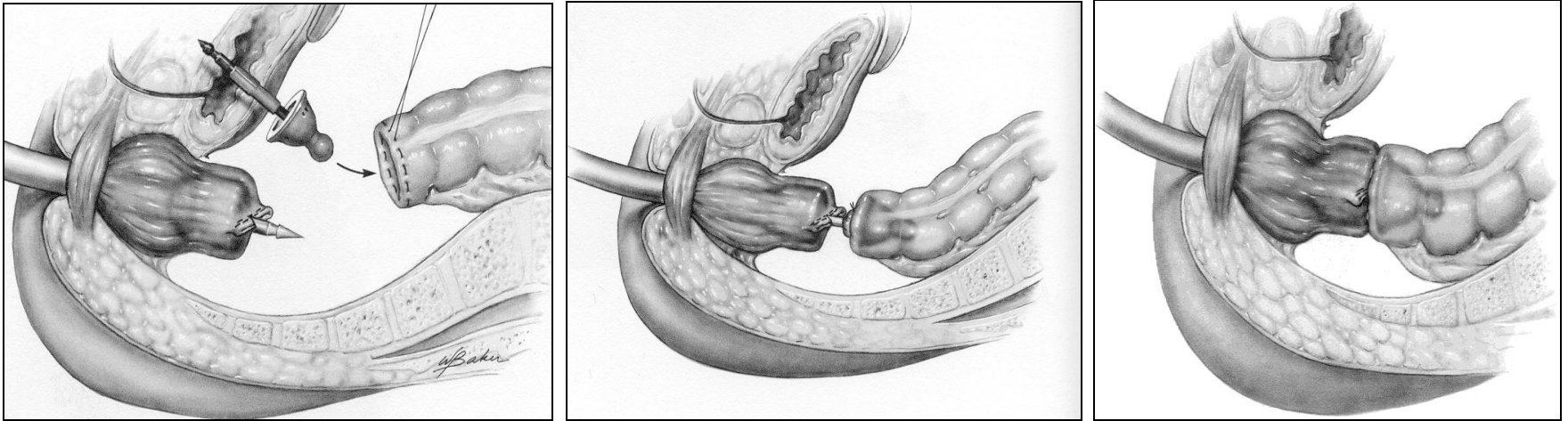


Partiële Mesorectale Excisie



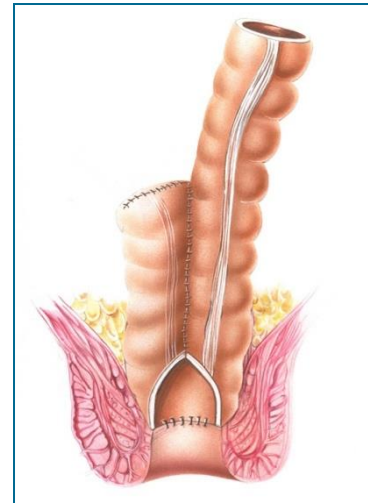
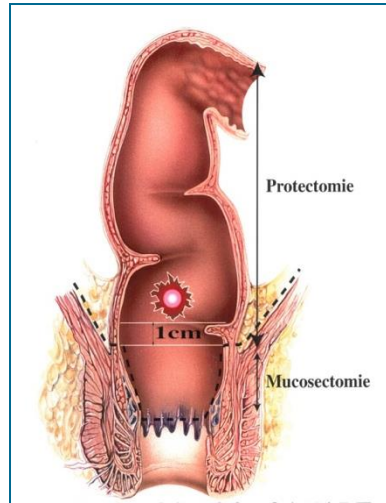
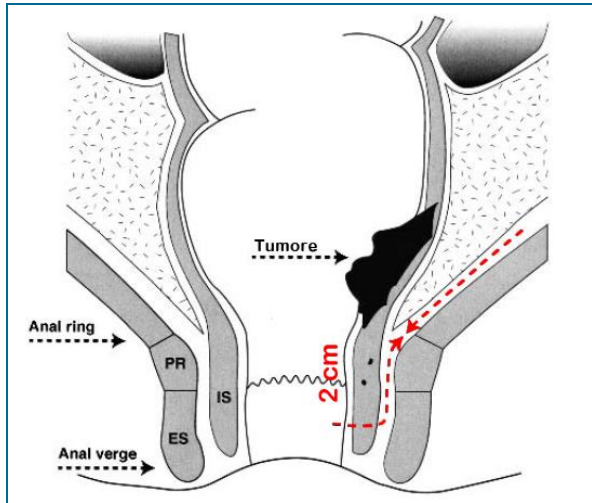
Totale Mesorectale Excisie

Colo-rectale anastomose

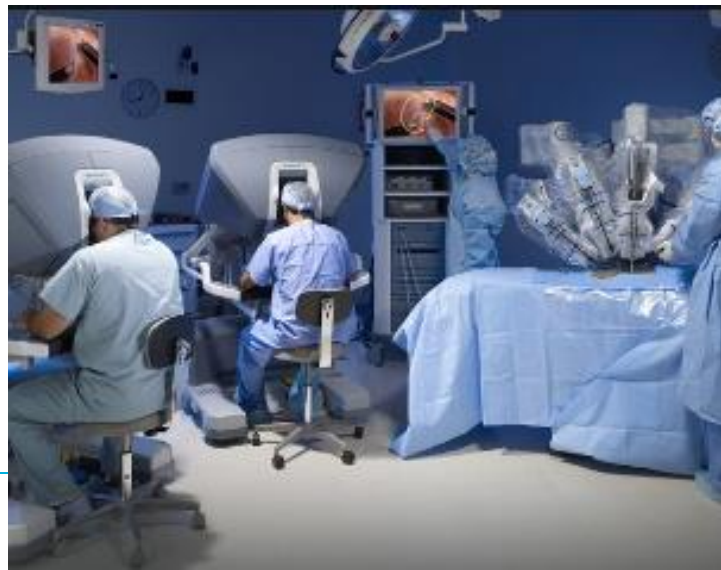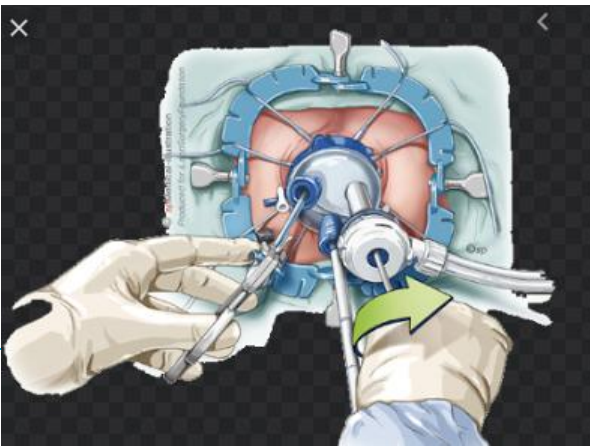

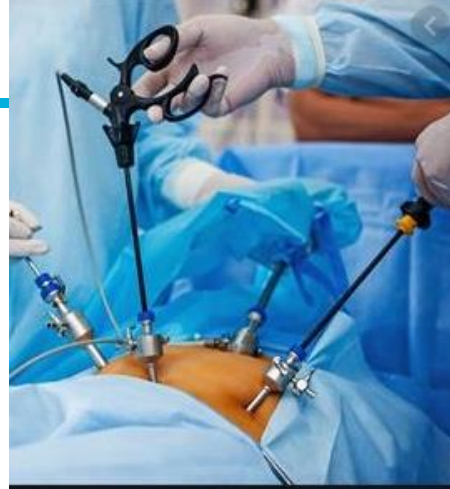
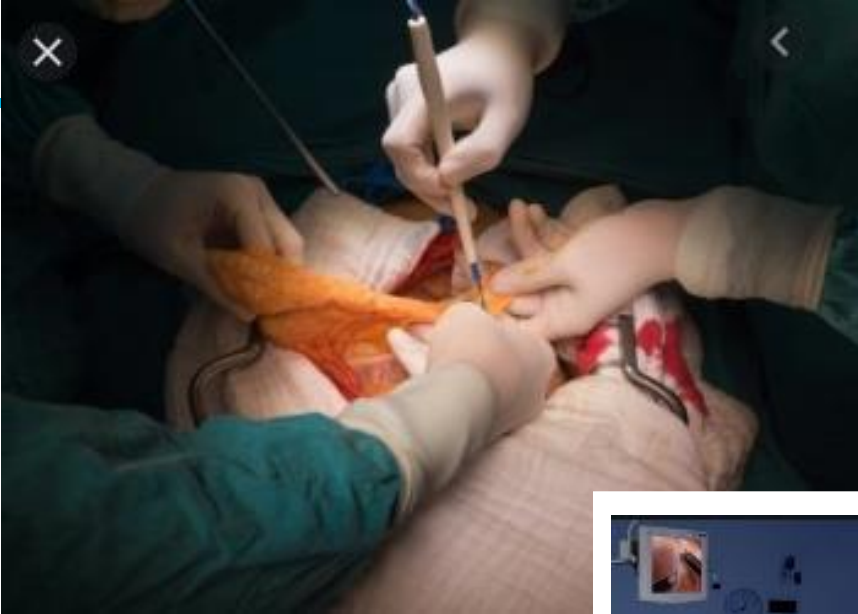Double staple techniek

Colo-anele anastomose



Hand gelegde anastomose

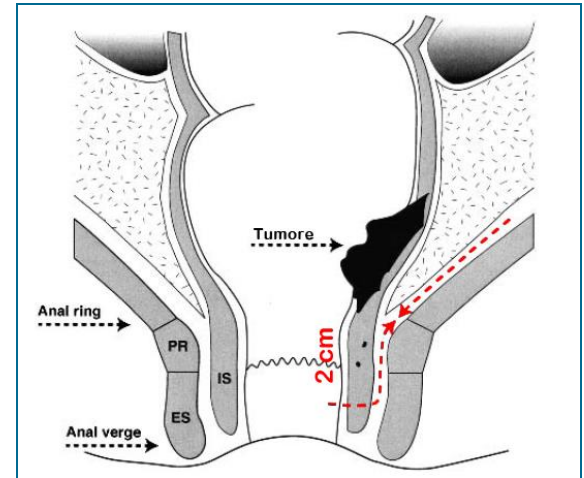


Abdominoperineale resectie

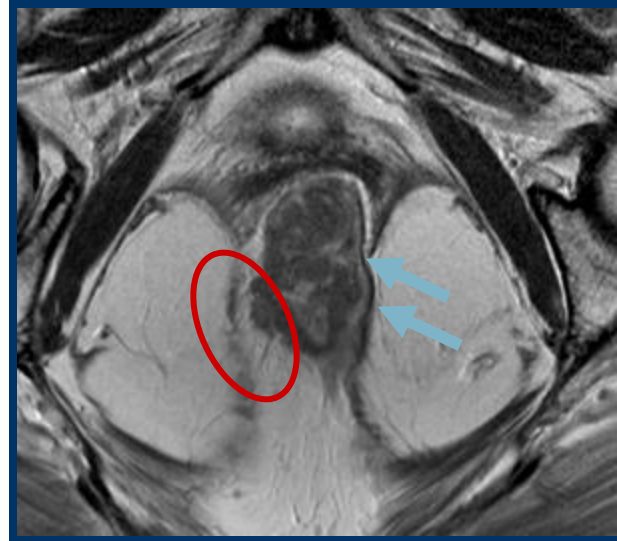
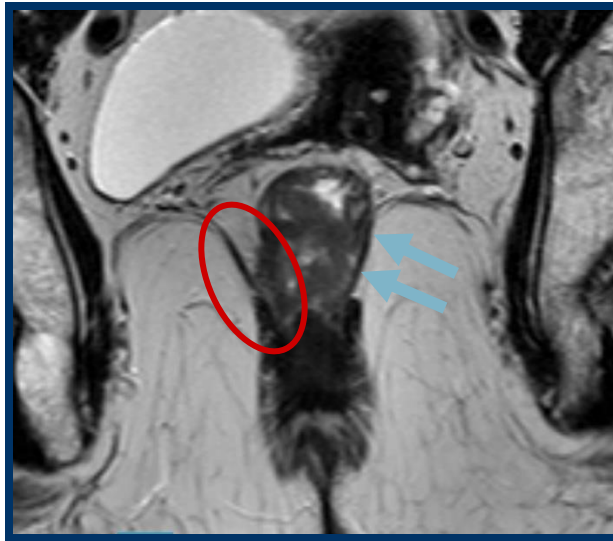
- Intersphincterische APR
- Extralevator APR
- Beyond TME (bijvoorbeeld: achterste exenteratie)

Intersphincterische APR

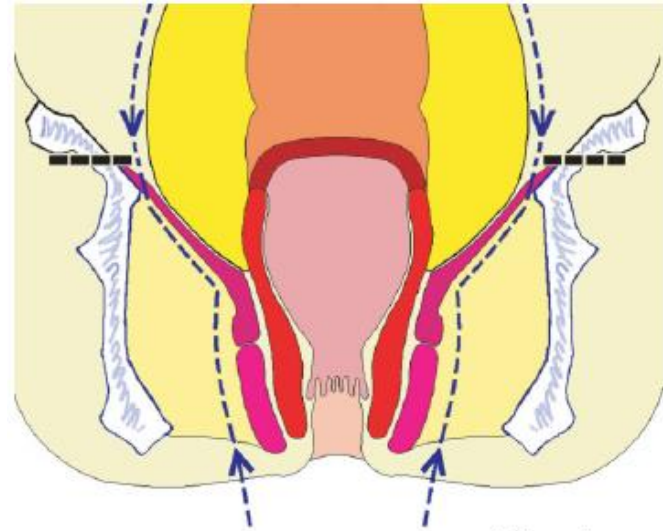
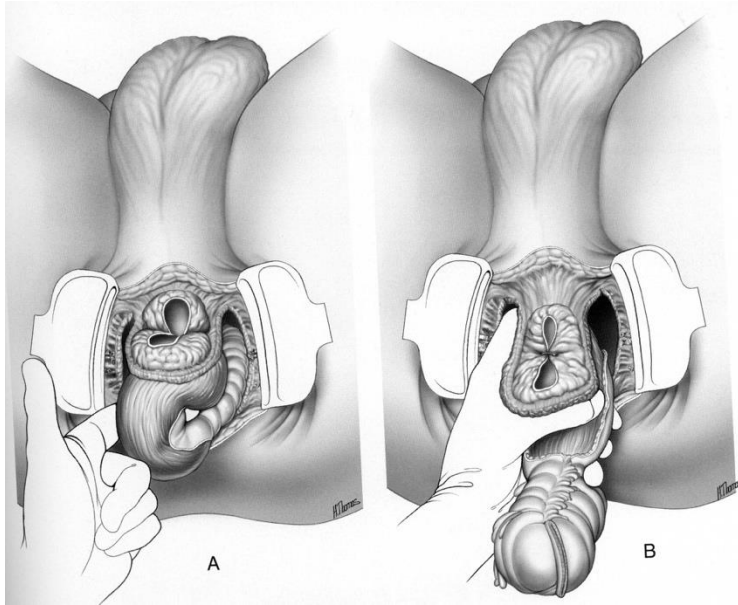
- Geen ingroei in levator
- Geen ingroei in sphincter
- Ipv Hartmann (staplen boven bekkenbodem)
- Colo-anaale anastomose
- Patienten waarbij geen anastomose:
 - Leeftijd
 - Co-morbiditeit
 - Keuze patiënt



Ingroei in levator

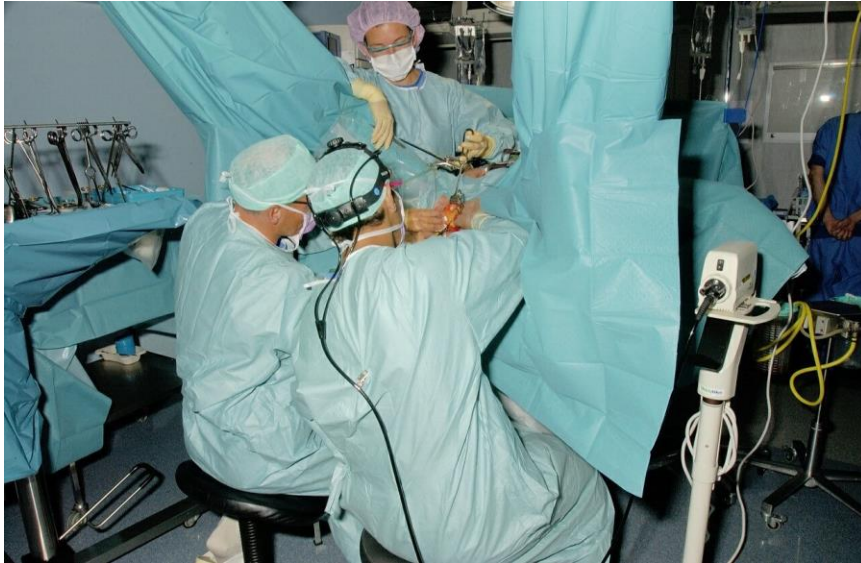

Extralevatoire AbdominoPerineale Resectie

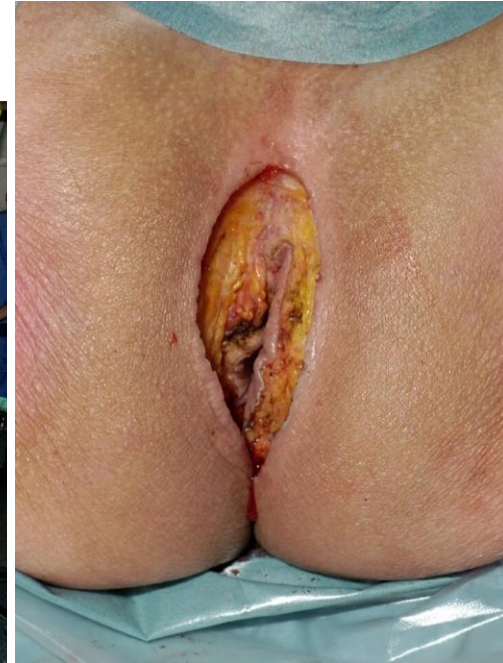

---> Resection lines
- - - - Level at which resection lines meet

APR

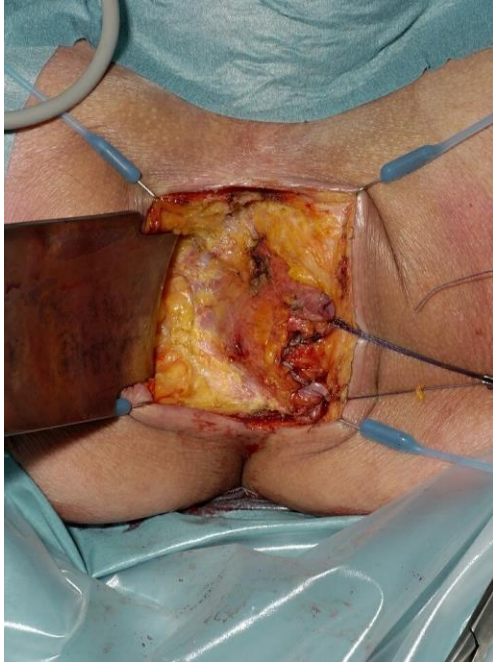


Trendelenberg position of the patient



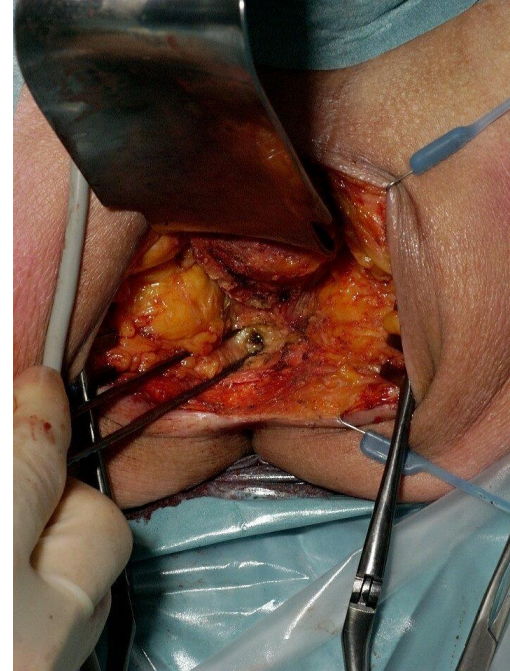
Excision of perianal skin

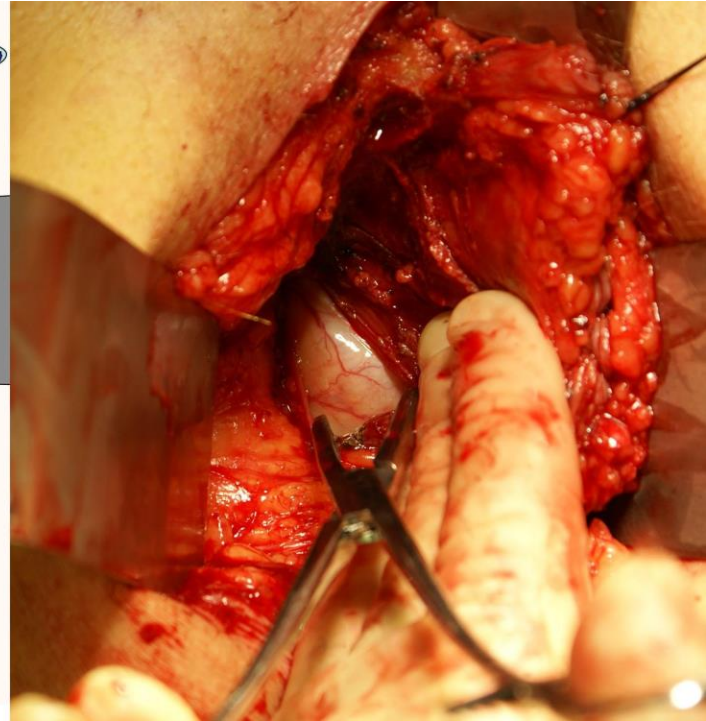
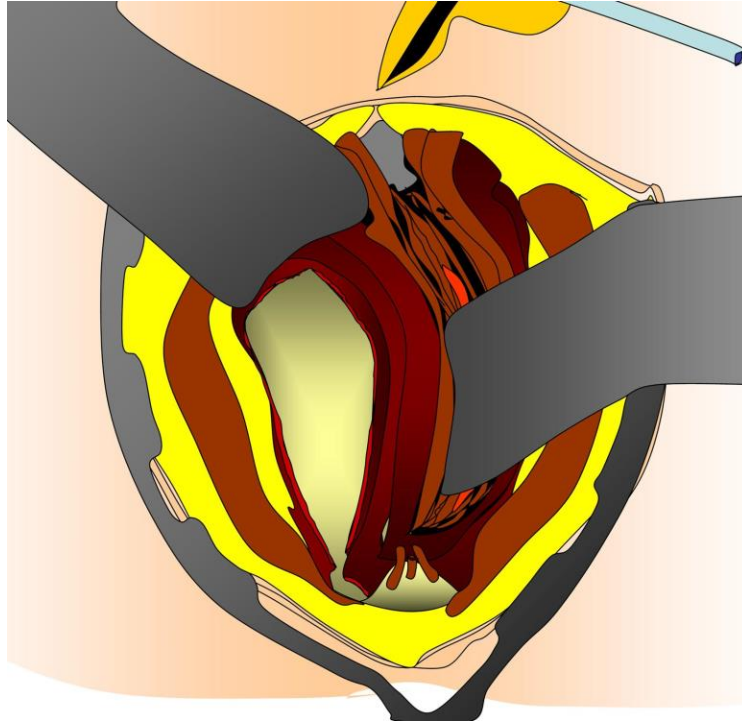
APR

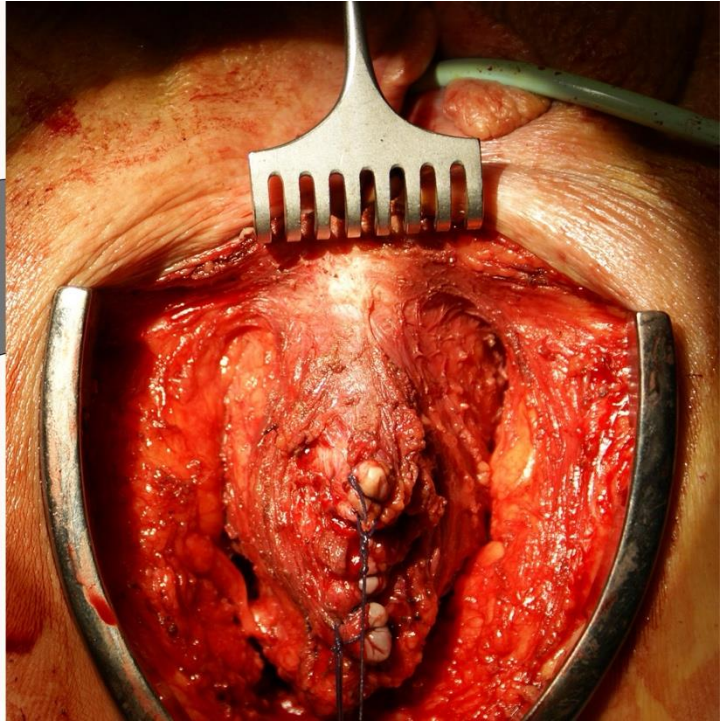
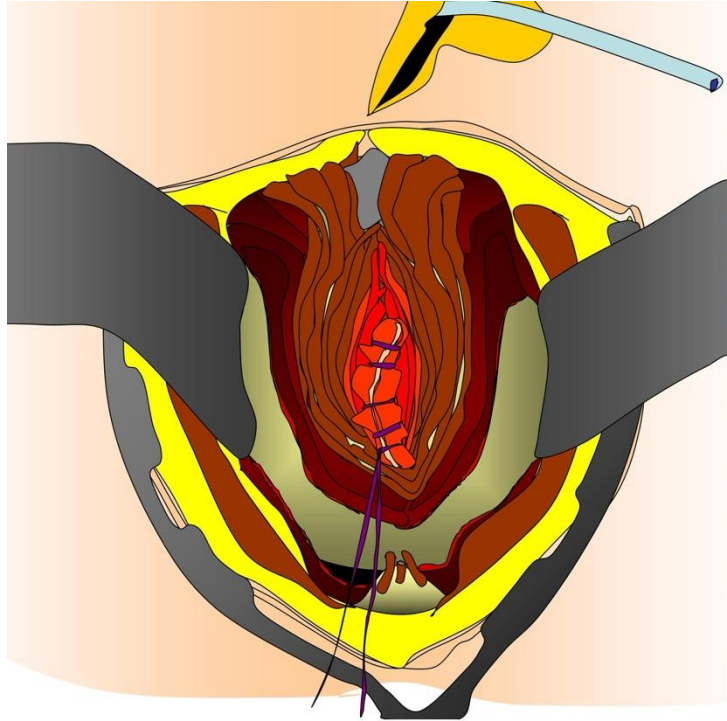


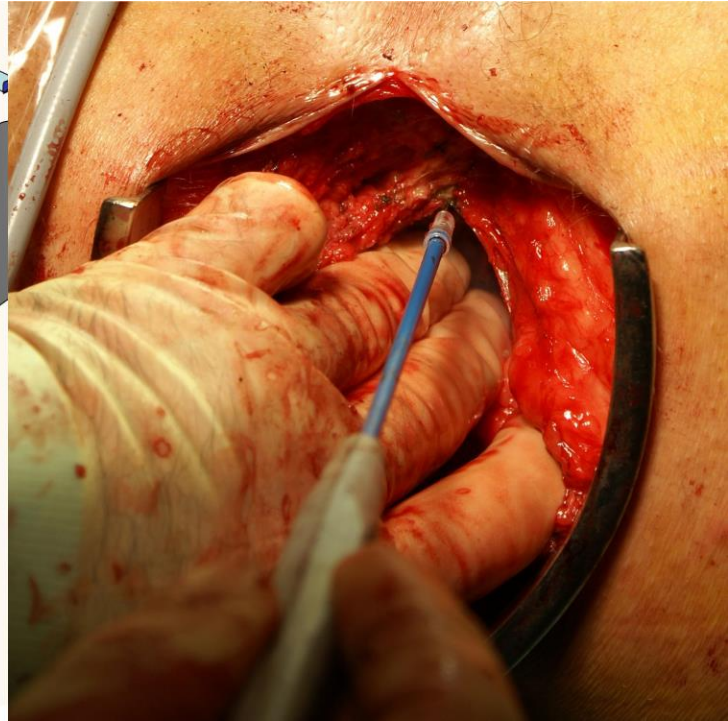
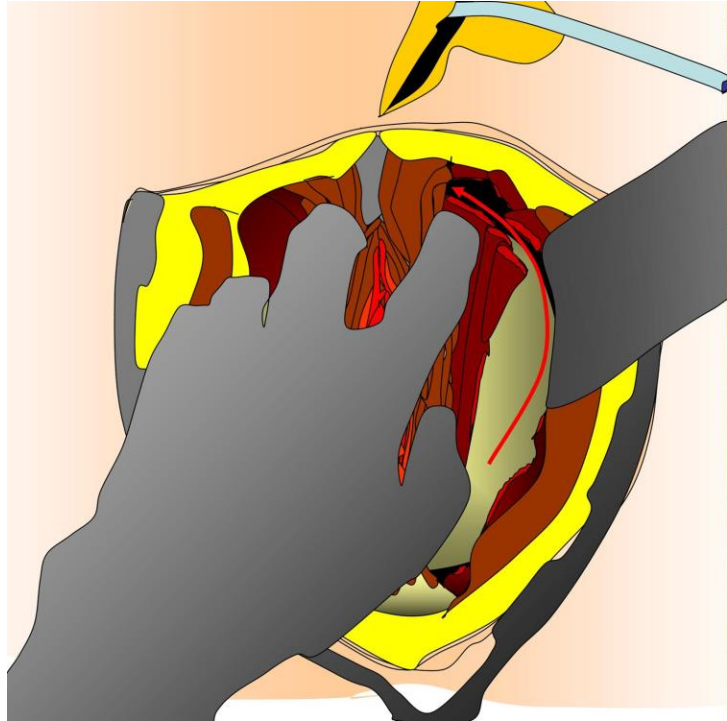
Stay close to the external sphincter

Coccyx

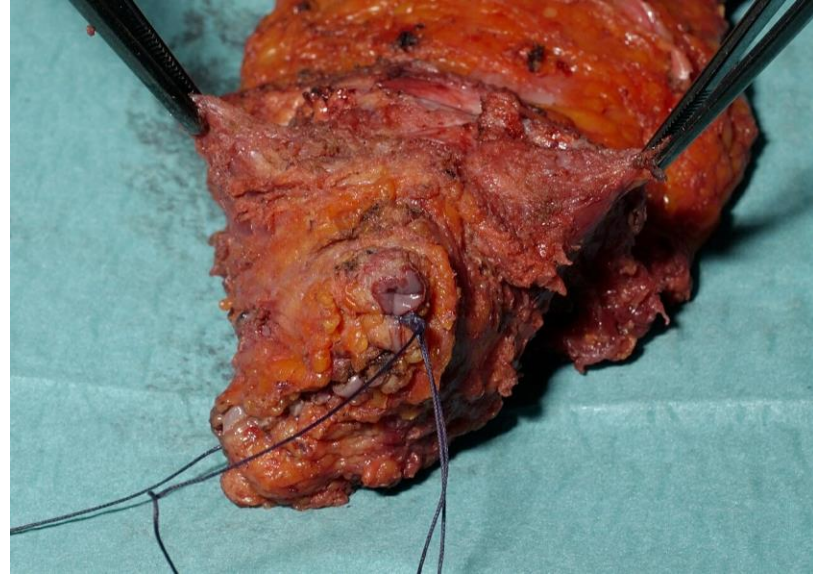
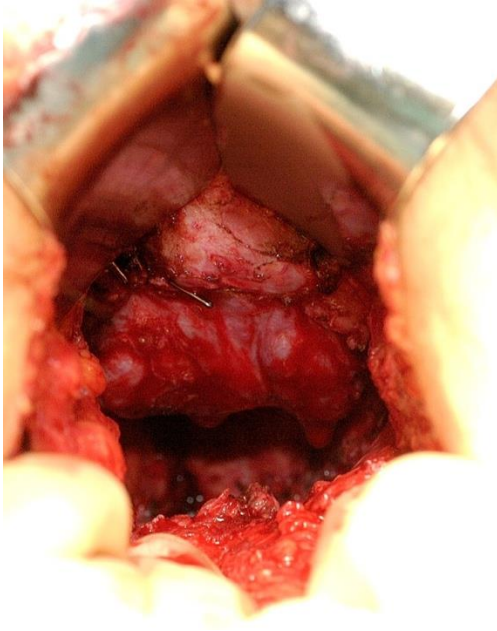






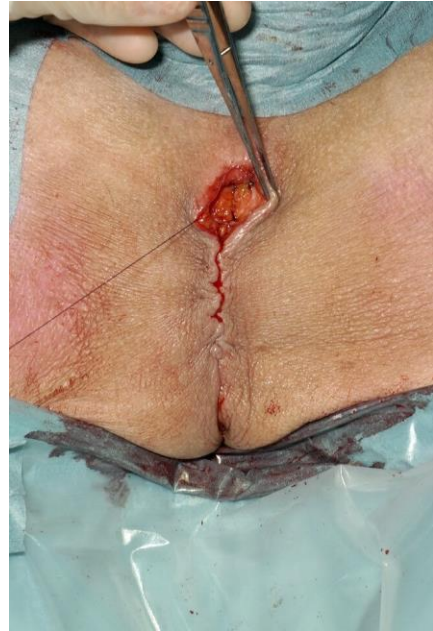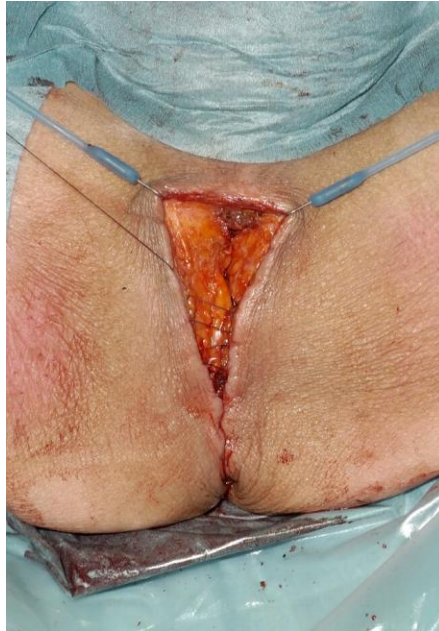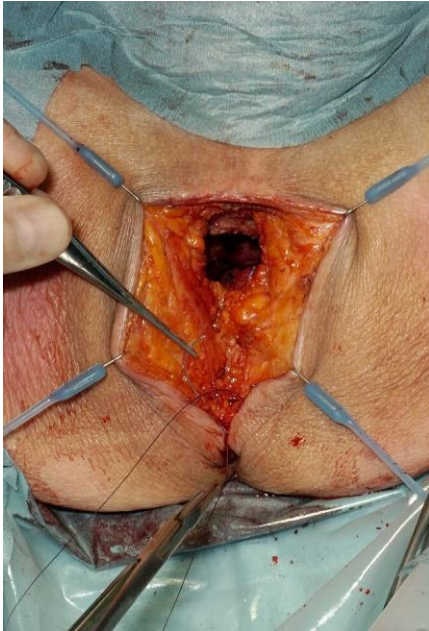


APR



TME specimen including levator muscles

APR



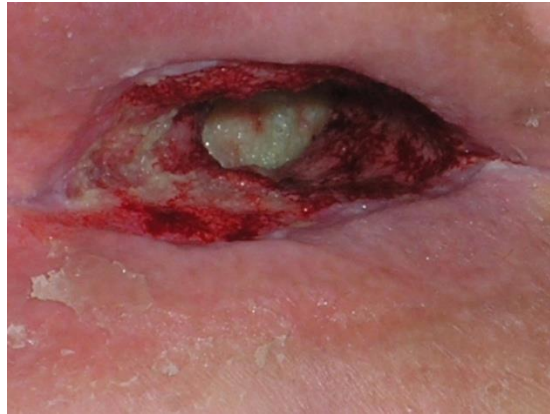
Meticulous closure of subcutaneous fat and skin

Perineale wond sluiten na APR

- Controle haemostase
- Reconstructie bekken (omentum, coecum, mesh, VRAM, gluteal turnover flap, ...)
- Sluiten subcutaan vet (bekkenbodem kan niet!)
- Sluiten huid

Complicaties perineale wond:

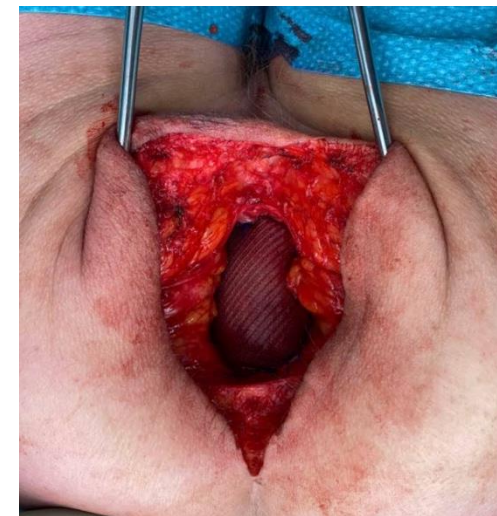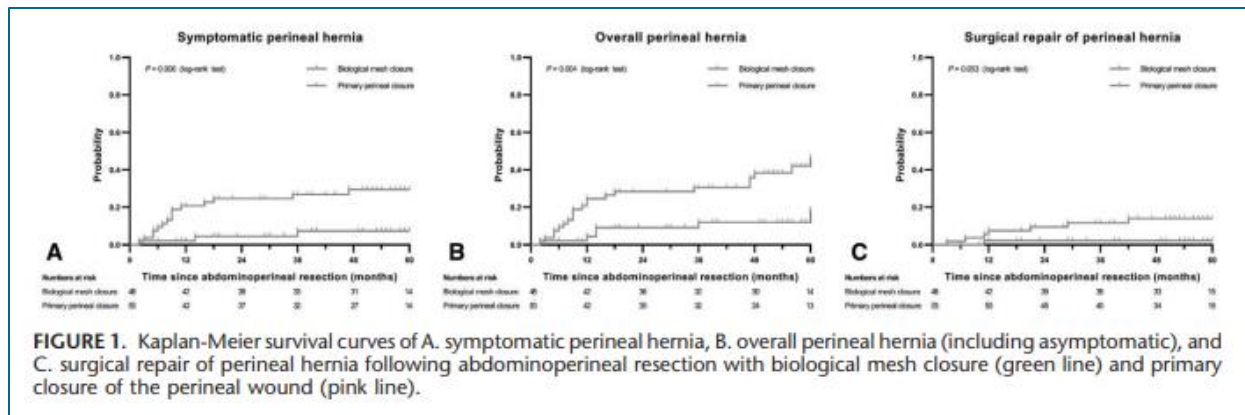
- Infectie, wondgenezingsstoornis
- Pijn
- Hernia




Cumulative 5-year Results of a Randomized Controlled Trial Comparing Biological Mesh With Primary Perineal Wound Closure After Extralevator Abdominoperineal Resection (BIOPEX-study)

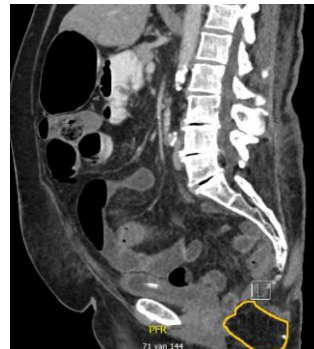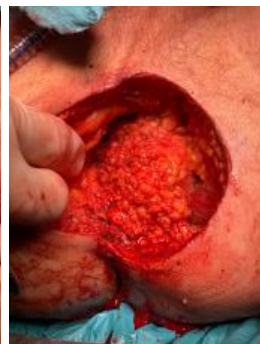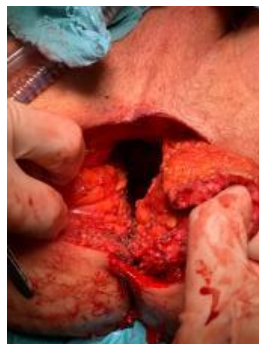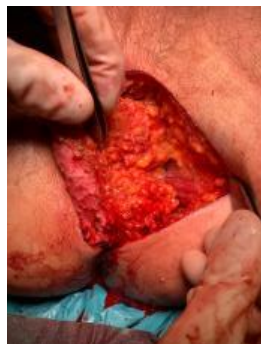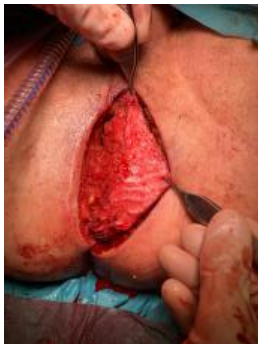Robin D. Blok, MD,^{*,†} Sarah Sharabiany, MD,^{*} Jaap Stoker, MD, PhD,[‡] Ellen T. M. Laan, MD, PhD,[§]
 Robbert J. I. Bosker, MD, PhD,^{||} Jacobus W. A. Burger, MD, PhD,[¶] Sanjay Chaudhri, MD,[#]
 Peter van Duijvendijk, MD, PhD,^{**} Boudewijn van Etten, MD, PhD,^{††} Anna A. W. van Geloven, MD, PhD,^{‡‡}
 Eelco J. R. de Graaf, MD, PhD,^{§§} Christiaan Hoff, MD,^{||||} Roel Hompes, MD, PhD,^{*}
 Jeroen W. A. Leijten, MD,^{¶¶} Joost Rothbarth, MD, PhD,^{##} Harm J. T. Rutten, MD, PhD,^{¶¶}
 Baljit Singh, MD, PhD,[#] Ronald J. C. L. M. Vuytsteke, MD, PhD,^{***} Johannes H. W. de Wilt, MD, PhD,^{†††}
 Marcel G. W. Dijkgraaf, PhD,^{‡‡‡} Willem A. Bemelman, MD, PhD,^{*}
 Gijsbert D. Musters, MD, PhD,^{*} and Pieter J. Tanis, MD, PhD^{*✉}

- 30 dagen wondinfectie: geen verschil
- **Minder perineale hernia's**
- **Minder perineale hernia operaties**





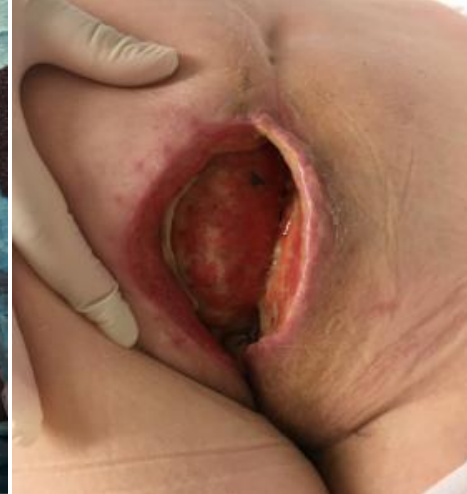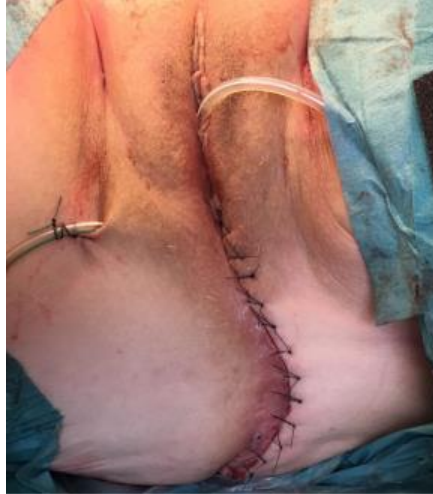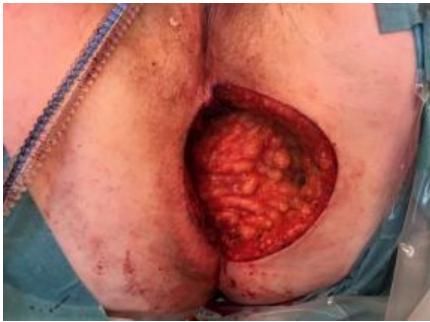Does the use of a **gluteal turnover flap** improve the primary perineal wound healing?



Blok et al. Tech Coloproctol 2017
Blok et al. Tech Coloproctol 2019

Blok et al. Colorectal Dis 2019
Sharabiyan et al. BMC Surgery 2020

Phase III study



Geen verschil:

- 30 dagen wondinfectie
- Perineale hernia



Conclusie:

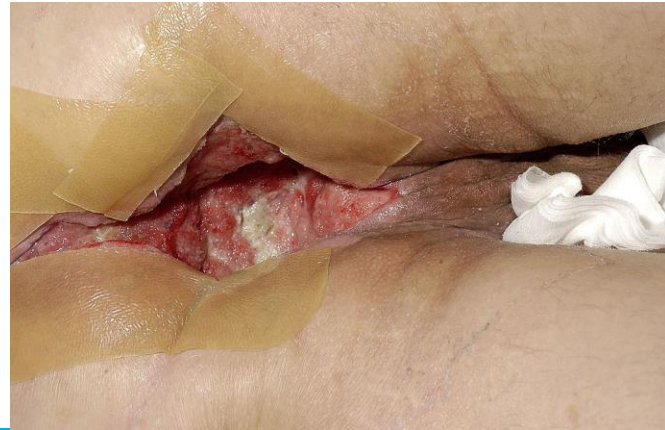
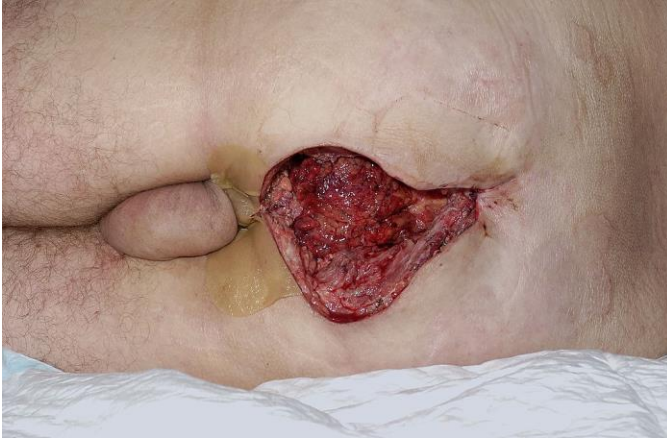
- Bij intersphincterische APR: i.p. nooit reconstructie
- Bij extralevatoire APR: i.p. geen reconstructie

Wanneer wel:

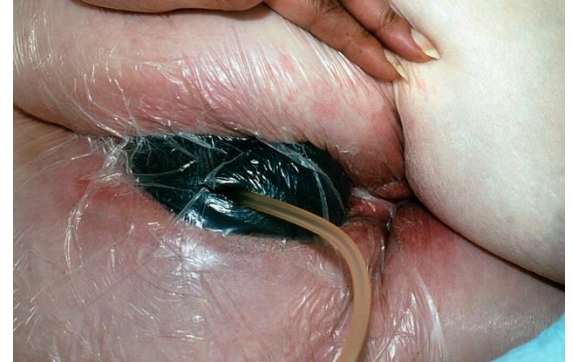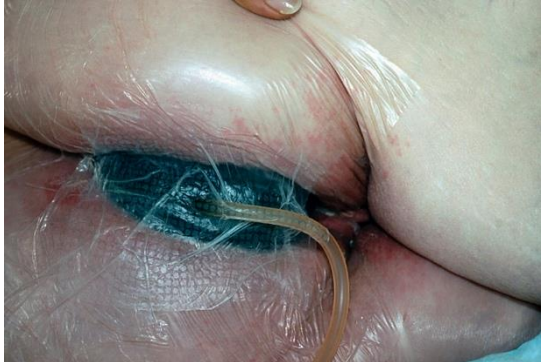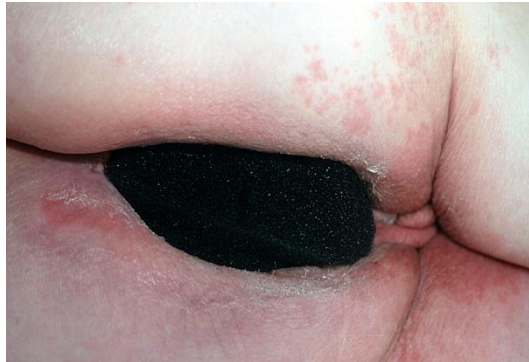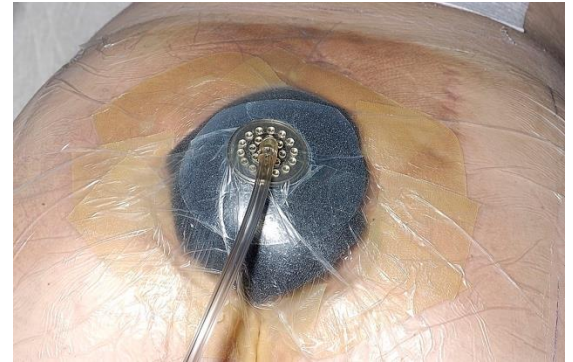
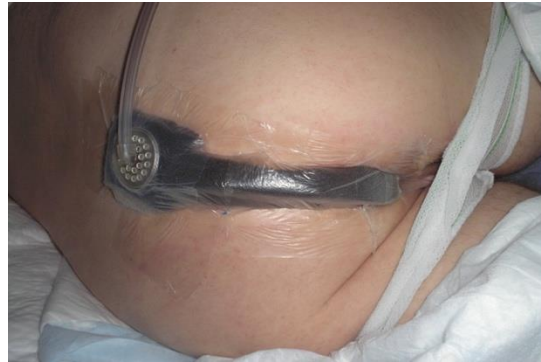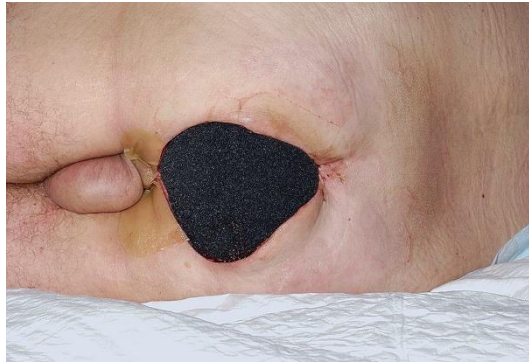- Bij langdurige wondinfecties: Overweeg reconstructie na VAC therapie
- Bij beyond TME: i.p. reconstructie
- Bij salvage APR in verband met anuscarcinoom: i.p. reconstructie
(hoge dosis radiotherapie gehad!)

Tijdelijke VAC behandeling bij perineale wondinfectie

- Mannen: relatief eenvoudig
- Vrouwen: veel lekkage



Tijdelijke VAC behandeling



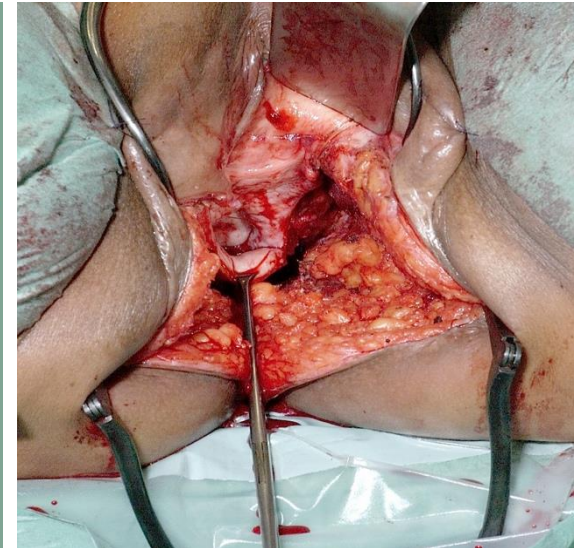
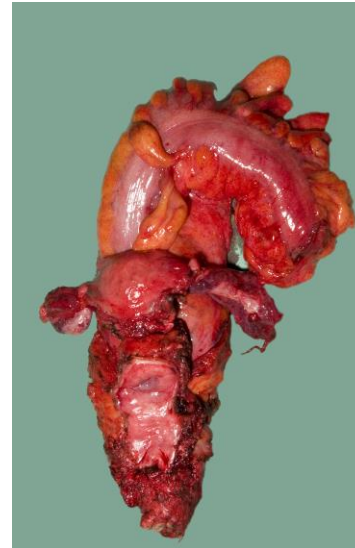
Achterste/totaal exenteratie

Multiviscerale resectie met meenemen van:

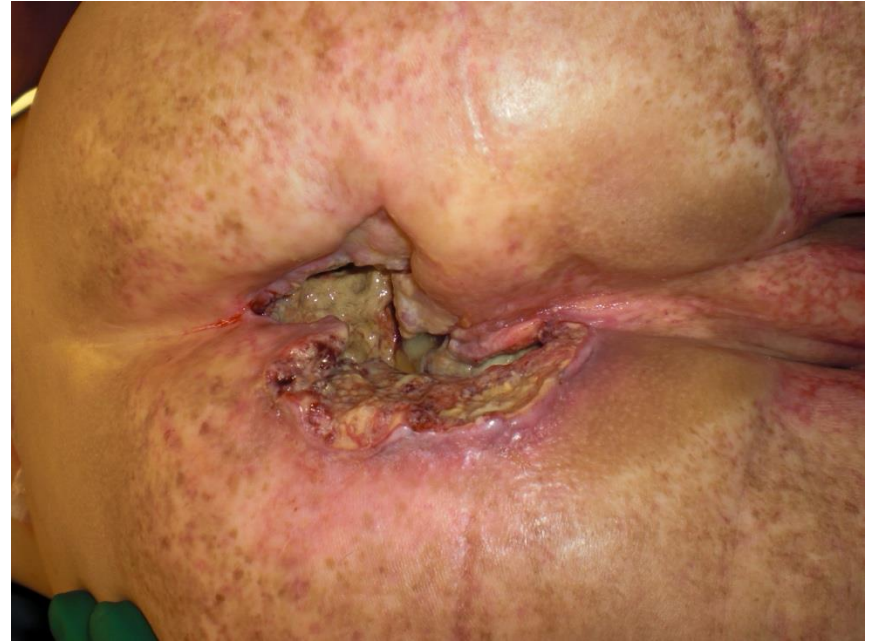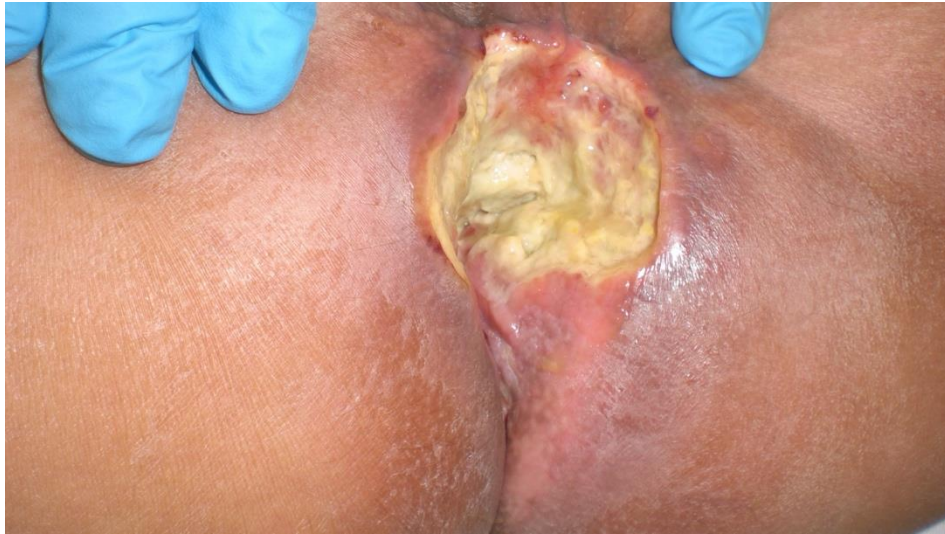Voorste: Blaas, Uterus, Adnexen

Achterste: Vagina, Uterus, Adnexen + rectum

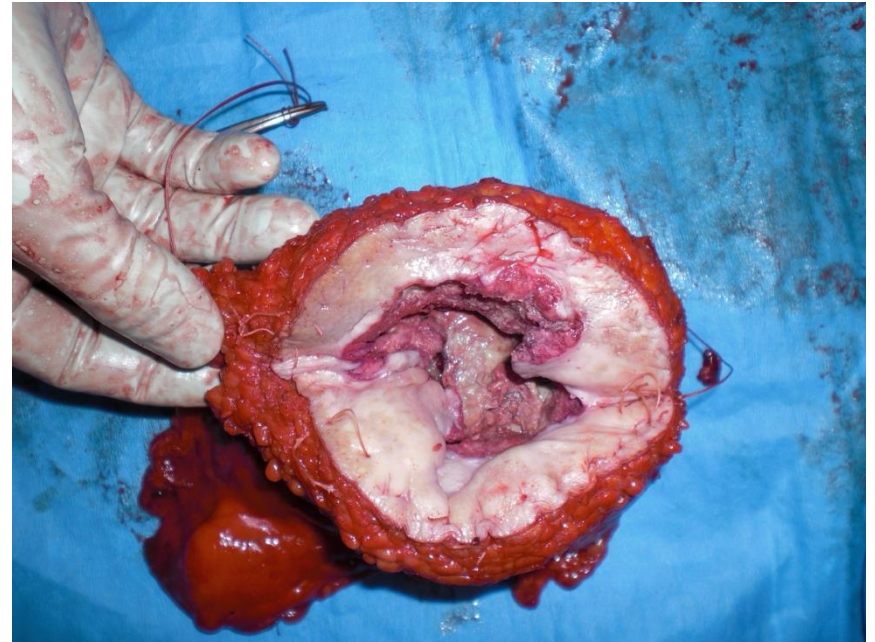
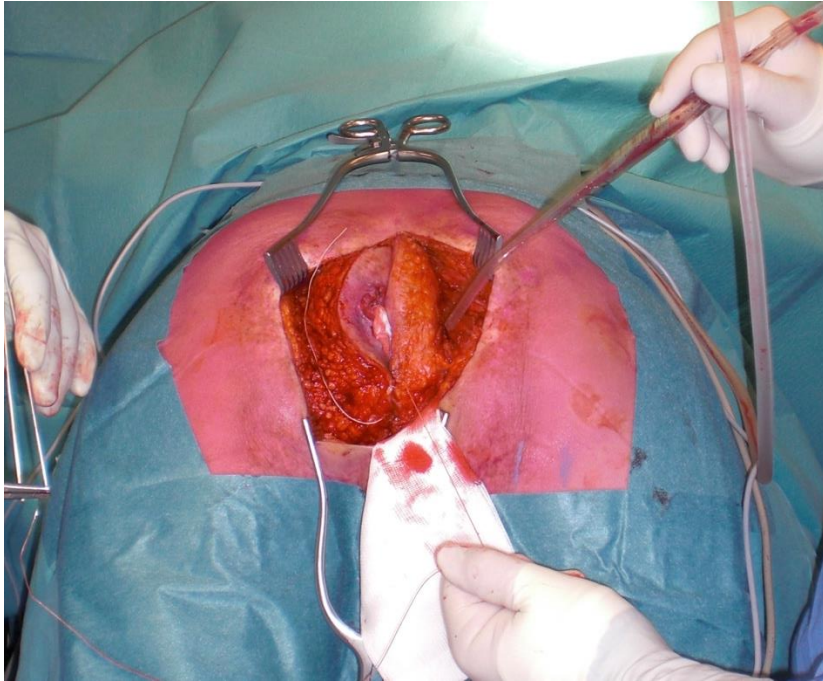
Totaal: Prostaat, Blaas, Vesikels + rectum
(urostoma)



Recidief anuscarcinoom



Recidief anuscarcinoom



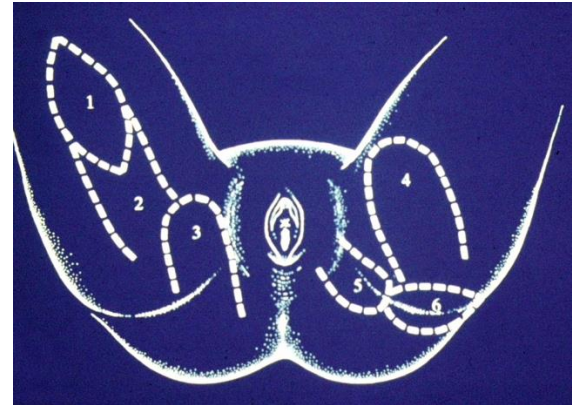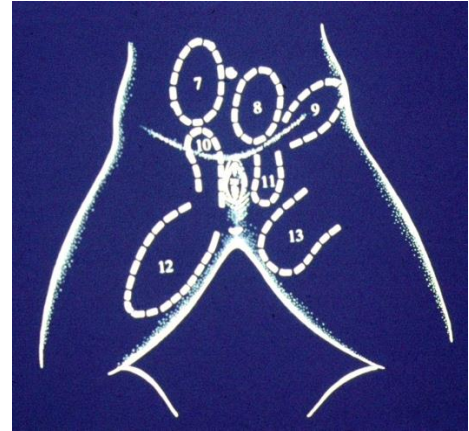
Tissue transfer:

Free:

- Latissimus dorsi flap

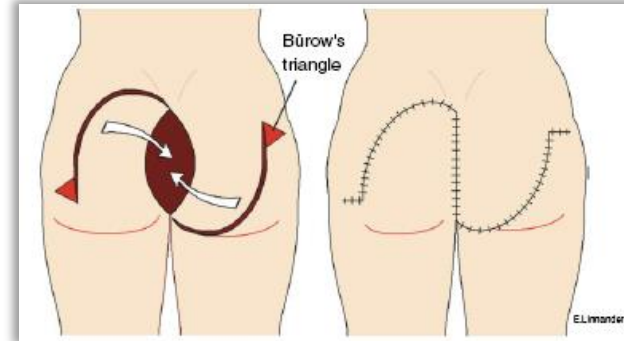
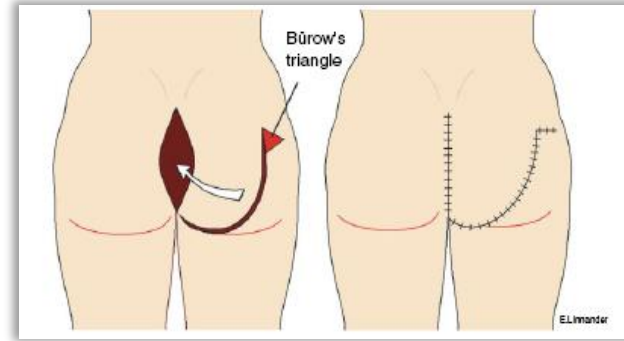
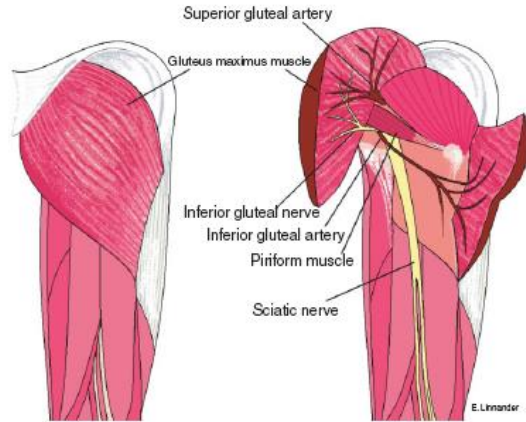
Pedicled:

- Local transposition
- Omental flap
- Gracilis flap
- Rectus Abdominis flap



Local transposition

- Gluteus maximus transposition



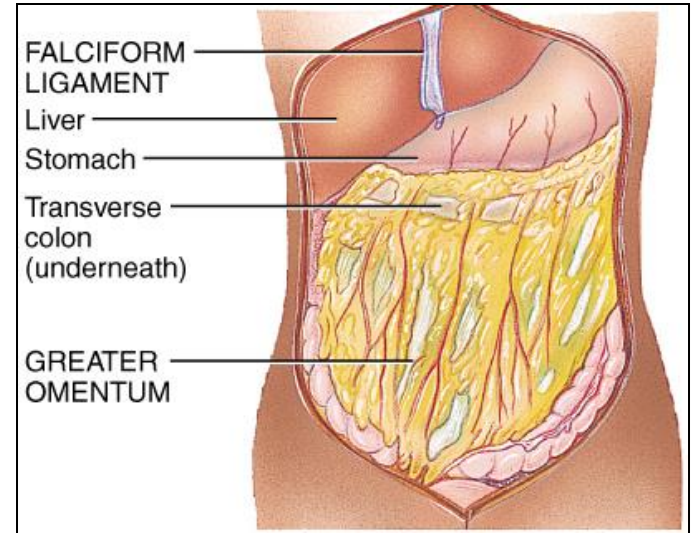
Omentoplastiek

Pro

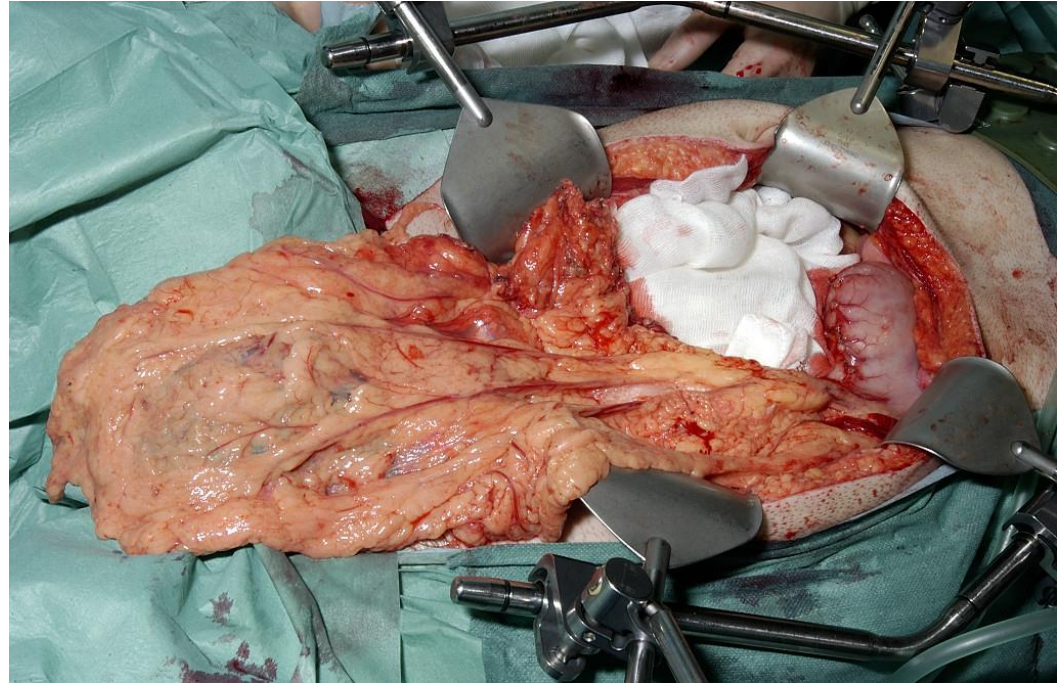
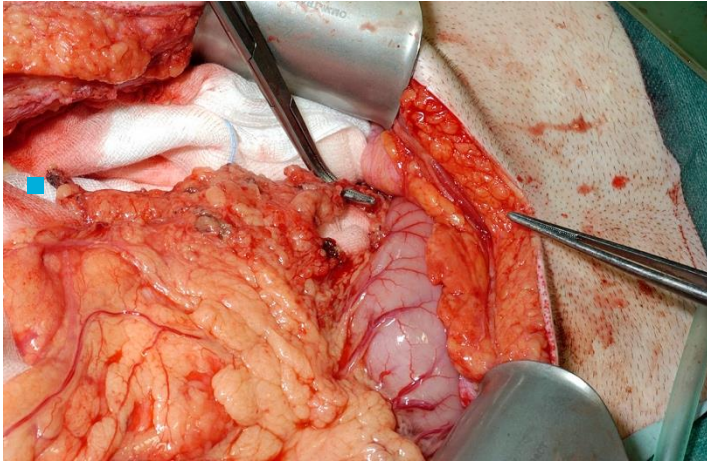
- Haemostatisch
- Goed gevasculariseerd
- Niet-bestraald gebied
- Volume

Con

- Complicaties (maagontleding)
- Technisch lastig
- Necrose distale deel
- Volume beperkt (slanke patiënt)



Omentumplastiek

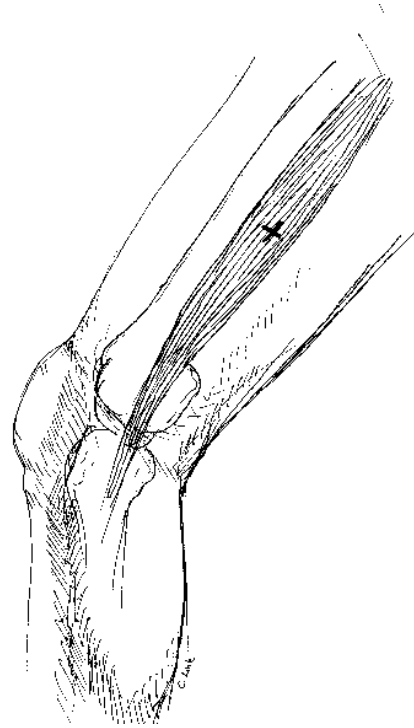


Musculus Gracilis

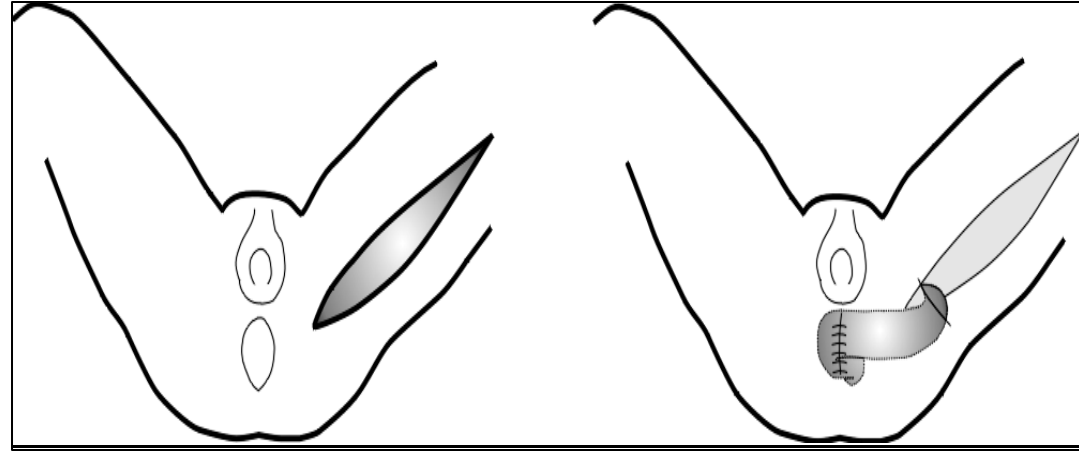
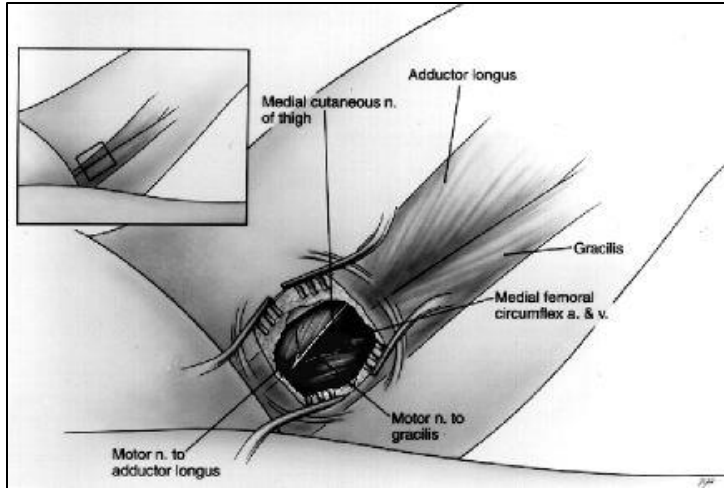
- Bilateraal
- Mogelijk in nauwe bekkenwond
- Geen laparotomie nodig
- Lage morbiditeit
- Been functie intact

Nadelen:

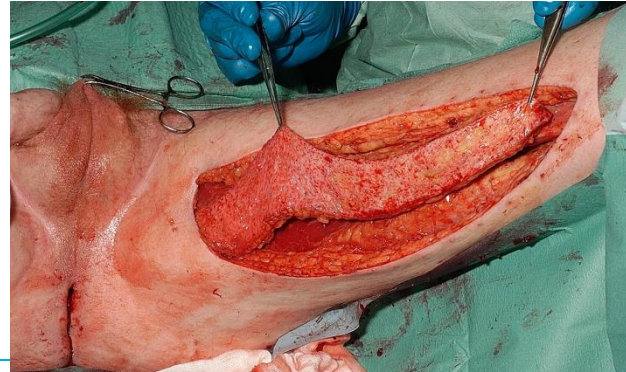
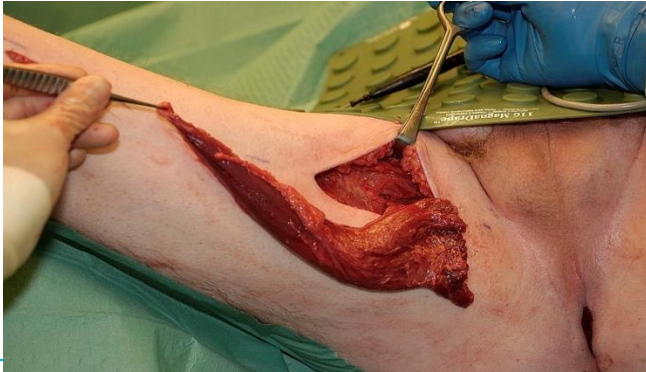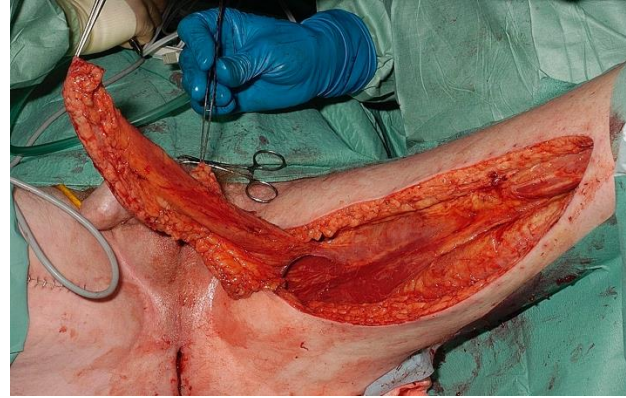
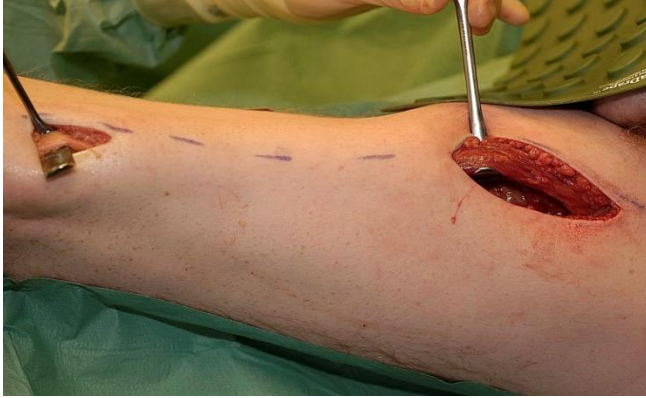- Klein volume
- Vascularisatie fragiel
- Huid eiland onbetrouwbaar



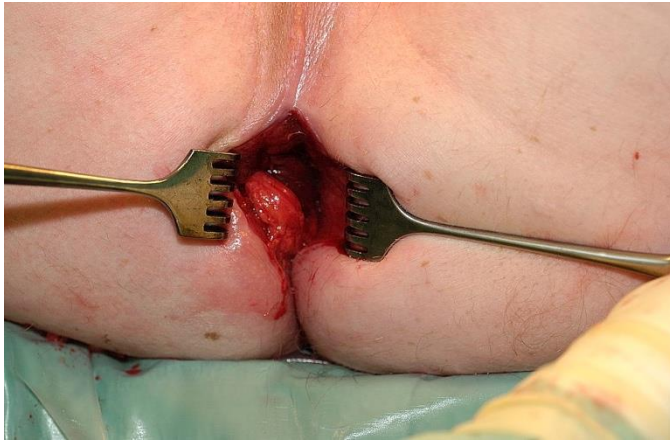
Musculus gracilis transposition



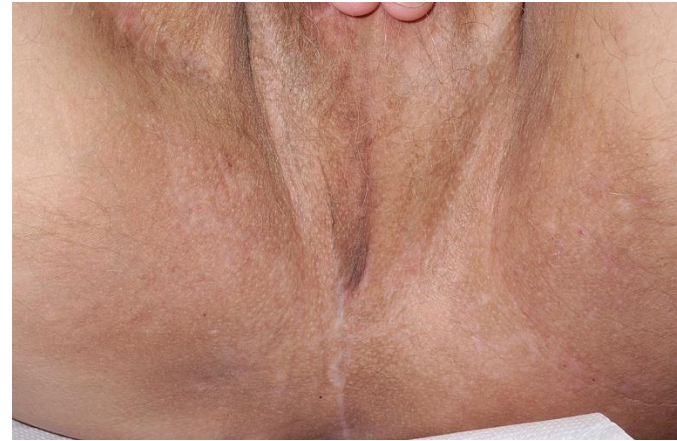Musculus gracilis transposition



Musculus gracilis transposition

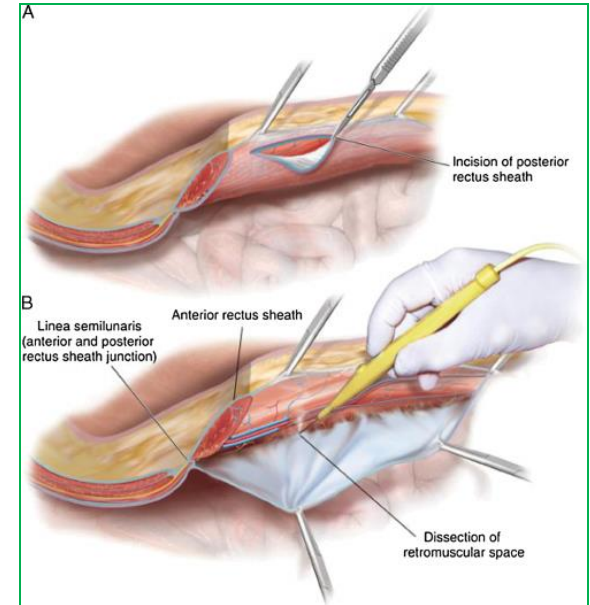
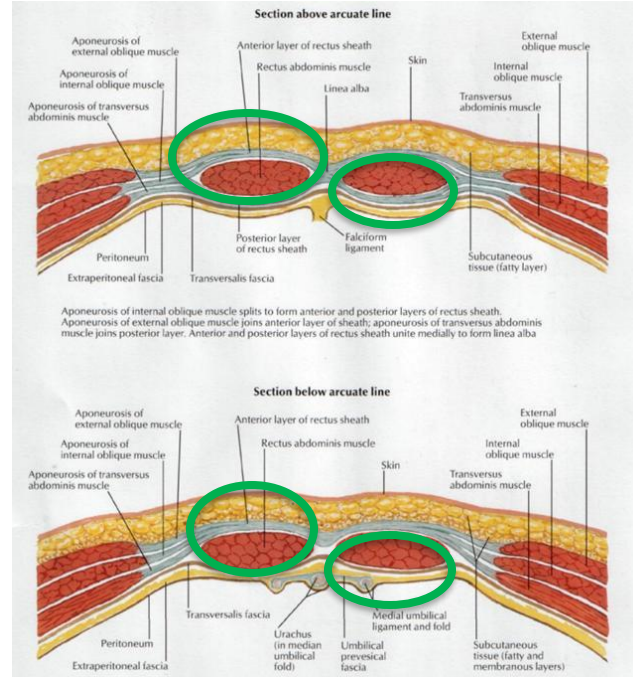
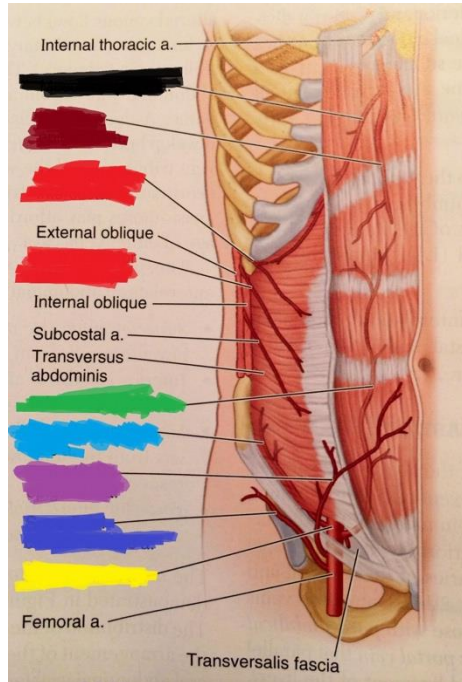


Peroperative result

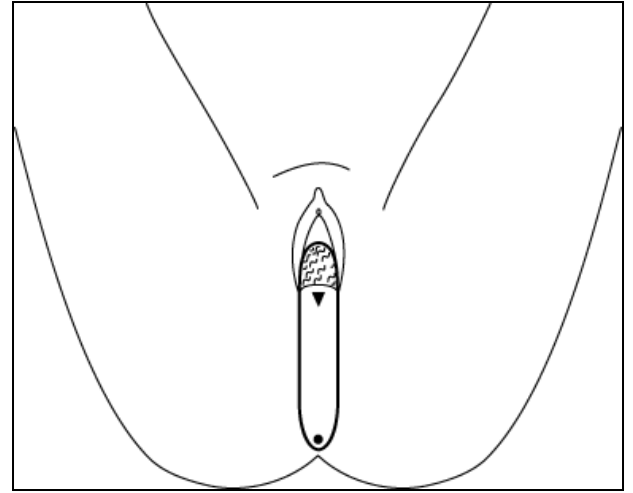
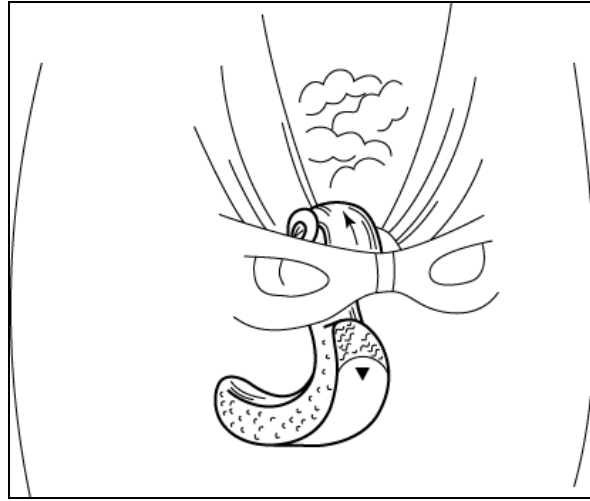
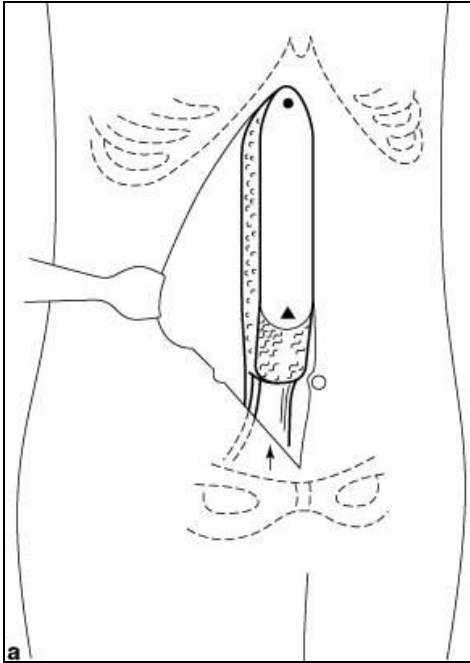


Two months postoperative

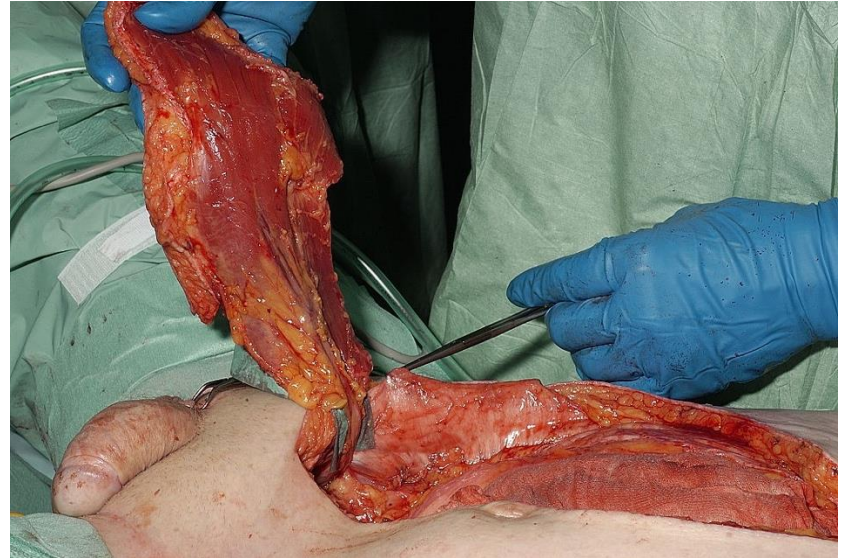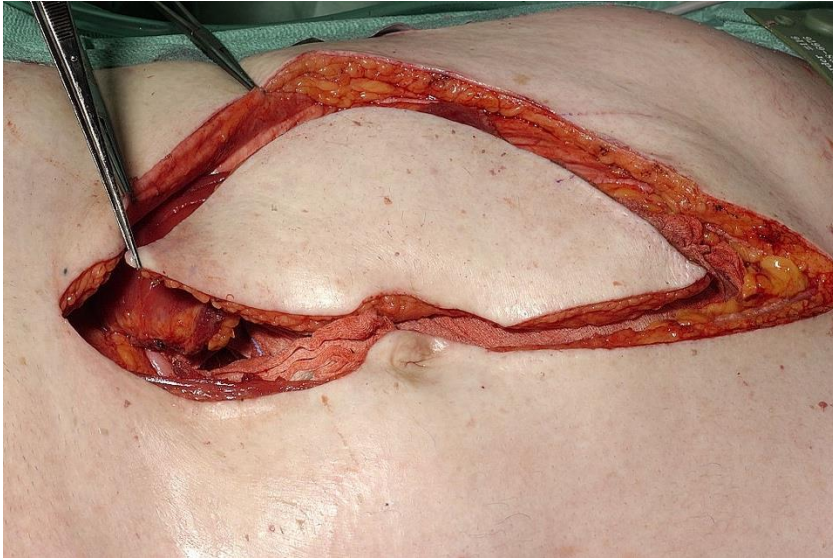
Verticale Rectus Abdominus Muscle



Verticale Rectus Abdominus Muscle

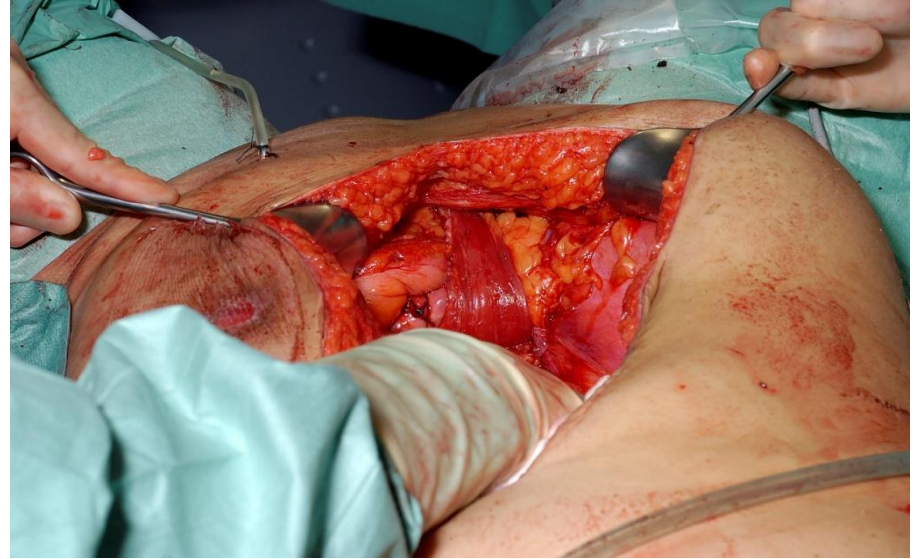
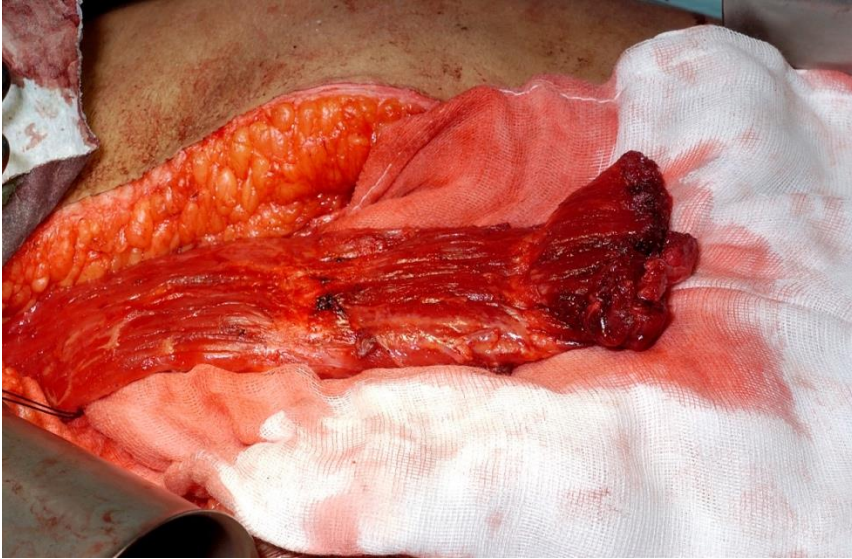


Verticale Rectus Abdominus Muscle



Met huideiland uitsnijden, voor perineale defecten

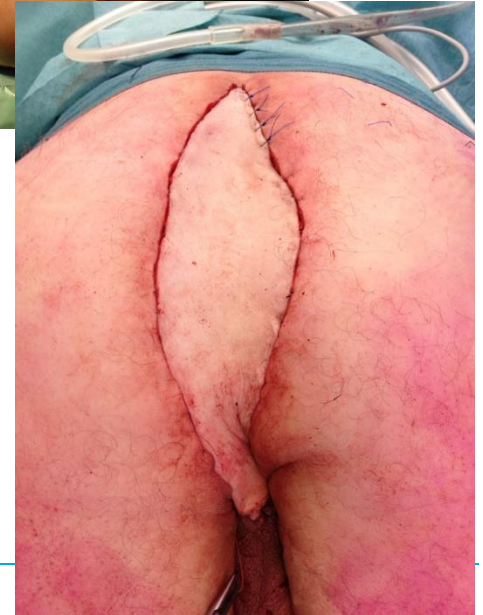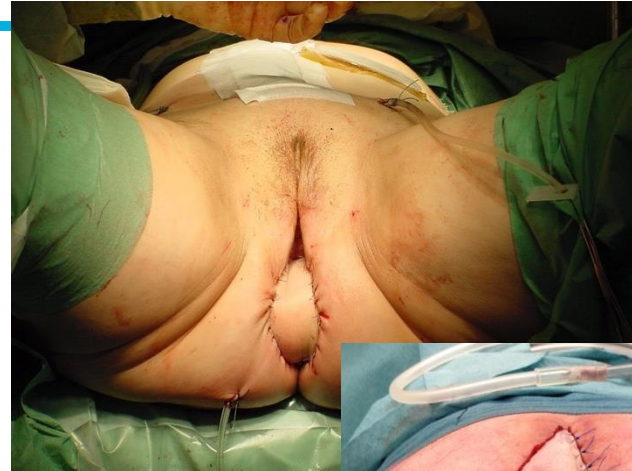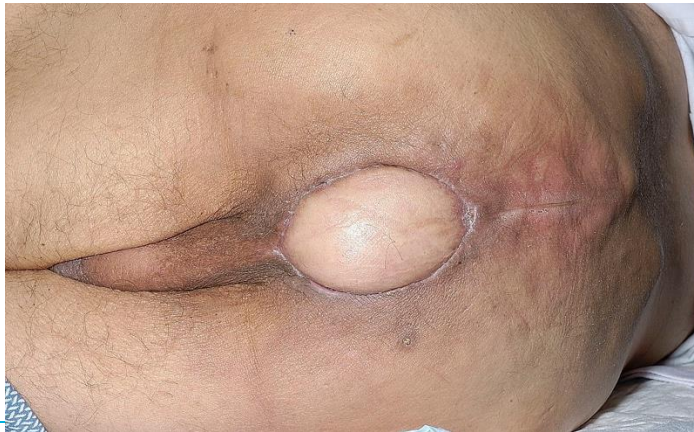Verticale Rectus Abdominus Muscle



Zonder huideiland uitsnijden, voor vaginale defecten

VRAM

- Sluiten defecten perineaal
- Reconstructie vagina
- Minder perineale infecties



Verpleegkundige aandachtspunten na APR

- Colostoma zorg
- Perineale wond
- SPC/CAD
- Drains in Douglas, perineum
- Voeding
- Wondinfectie
- Psychosociaal (lichaamsbeeld, seksualiteit, angst voor terugkeer kanker)
- Arbeid

Take Home Messages

- iAPR of eAPR In principe geen reconstructie nodig
- Reconstructie perineum: Locale tissue transfer, VRAM
- Reconstructie vagina: VRAM, Gracilis of omentumplastiek
- Perineale wondinfectie Debridement
VAC
Locale tissue transfer, Gracilis



Dank voor aandacht

